

Understanding Heart Muscle Organisation in Dilated Cardiomyopathy



Introduction

Dilated Cardiomyopathy is a disease of the myocardium (heart tissue) [1]. The left ventricle enlarges, the muscle wall thins, the heart is less effective at pumping the blood around the body (Fig.1). The molecular basis of most DCM cases is unclear [2]. Treatment includes medications, devices, or heart transplant. A better understanding of how heart structure is affected in DCM could lead to new and better treatments [3].

α -actinin is found in the Z disc. Z-discs are found at the boundaries of muscle sarcomeres [4]. In normal heart cells, myofibrils are arranged in series (end to end) which gives a striated (stripy) pattern along the length of the cell (Fig. 2).

Aim

Here we used antibodies and Affimers to stain up proteins in human heart muscle samples to determine differences in DCM and healthy muscle organisation.

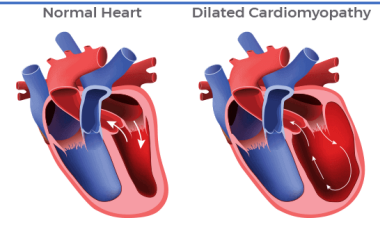


Fig. 1: Normal heart and DCM-affected heart (adapted from DCM Foundation, 2021)

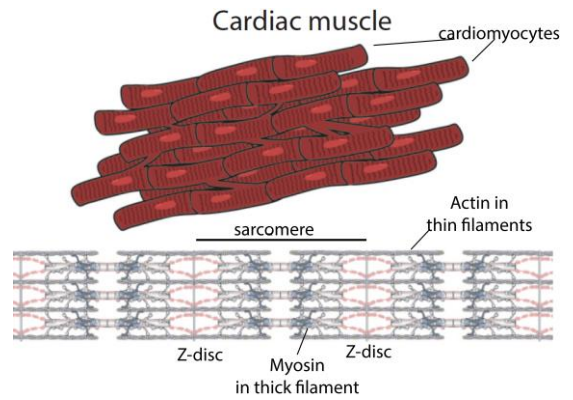



Fig. 2: Cardiac muscle (top) and myofibrils (bottom) (adapted from Powers et al., Annual Review of Biophysics. 2021. 50:373–400)

Methods

- Affimers were expressed, purified and labelled with a dye.
- Heart samples were provided by the University of Sydney Heart Bank
- Samples were stained and images collected using light and confocal microscopes.

Normal heart

DCM heart



Microscopy images of normal and DCM hearts stained for α -actinin (in Z-discs)

Results

- In healthy myocardial cells, α -actinin staining has a regular striped appearance in longitudinal sections.
- In DCM heart cells, striations lack this regular structure.

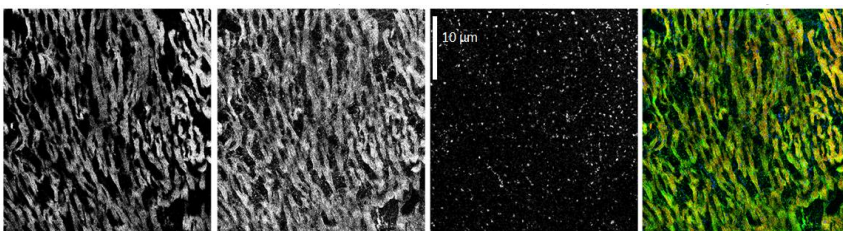
Myosin Affimer

α -actinin

DAPI


Merge

Longitudinal section



Myosin (LMM), α -actinin and nuclei DAPI) staining of a human DCM heart sample

Cross-section



Myosin (LMM), α -actinin and nuclei DAPI) staining of a human normal heart sample

Moving Forward: next steps

Test additional Affimers for Z-disc proteins (ZASP, myotilin) and sarcomeric proteins (myosin binding protein C).

Acknowledgements

Many thanks to Lord Laidlaw and the Laidlaw Foundation for the unique opportunity to conduct my own research at an early stage of my academic journey.

This project would not be possible without the support of my supervisor Michelle Peckham and Francine Parker. I am immensely grateful for the experience I have acquired in your laboratory.

Reference list

- [1] Mitrut, R., Stepan, A. E., Pirci, D. 2018. Histopathological Aspects of the Myocardium in Dilated Cardiomyopathy. *Current health sciences Journal*. Volume 44, pp. 243–249.
- [2] Roura, S., Gálvez-Montón, C., Lupón, J., Bayes-Genis, A. 2017. London: IntechOpen. *e Idiopathic Dilated Cardiomyopathy: Molecular Basis and Distilling Complexity to Advanc*
- [3] Verdonschot, J.A., Hazebroek, M. R., Ware J.S., Prasad S.K., Heymans S.R. 2019. Role of Targeted Therapy in Dilated Cardiomyopathy: The Challenging Road Toward a Personalised Approach. *Journal of the American Heart Association*. Volume 8, Issue 11
- [4] Barrett, K.E., Barman, S.M., Boitano, S., Brooks, H.L. 2012. *Ganong's Review of Medical Physiology*. 24th Ed. New York City: Tata McGraw Hill.