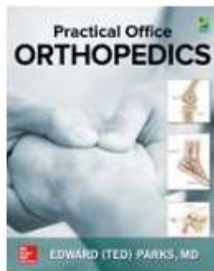


How do I link to an image or figure?



[View Contents](#)

< **Chapter 3** >

INTRODUCTION

HIP ARTHRITIS

GREATER TROCHANTERIC BURSITIS

LUMBAR SPINE PATHOLOGY

THE ZEBRAS ... LESS-COMMON CAUSES OF HIP PAIN

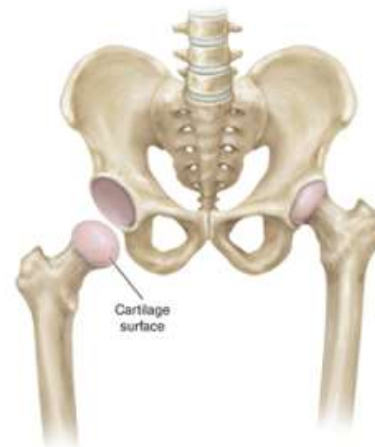HIP FRACTURES

View Print Share Get Citation Search Book Top

gone completely, exposing the underlying bone. Bone is not slick and slippery; it is rough and abrasive. It isn't numb like articular cartilage either. It has a rich nerve supply and, as a result, is very sensitive and a poor bearing surface for a weight-bearing joint. Figure 3-2 shows an arthritic femoral head with a large area of worn cartilage and exposed bone.

FIGURE 3-1.

The ball and socket of a normal hip joint.



Source: Edward (Ted) Parks
Practical Office Orthopedics
Copyright © McGraw-Hill Ed. All rights reserved.

[Click View Full Size](#)

[View Full Size](#)

[Favorite Figure](#)

[Download Slide \(.ppt\)](#)

AccessMedicine >

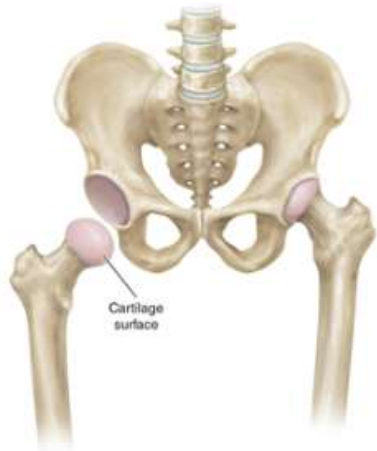Practical Office Orthopedics > The Hip

Edward (Ted) Parks

Figure 3-1.

The ball and socket of a normal hip joint.

[Download Slide \(.ppt\)](#) | [Print](#)



Source: Edward (Ted) Parks:
Practical Office Orthopedics
Copyright © McGraw-Hill Education. All rights reserved.

Copy URL

You may now copy this link and paste it into your Learning Management Tool or body of an email. Once you paste this link, the URL from the browser will link directly back to that image or table.